

# “Atypical debuts of Creutzfeldt–Jacob disease: Two Cases”

Anna Campana MD, Slater Karen, MD, Gaelle Rached, MD, MS, John Sanitato, MD, Anna Shapiro-Krew MD  
**Department of Psychiatry and Psychology, Neurological Institute, Cleveland Clinic Foundation (OH)**

## Introduction

- Creutzfeldt–Jacob disease (CJD) is a rapidly fatal form of dementia with an incidence of one per million individuals per year.
- CJD typically presents with neurological symptoms including progressive dementia, myoclonus, and extrapyramidal signs.
- Psychiatric disturbances constitute the prodromal manifestations in 18%-39% of the total cases, typically including depression, anxiety, or insomnia.
- More rarely, patients present with mania, psychosis or catatonia.

## Cases Series Presentation

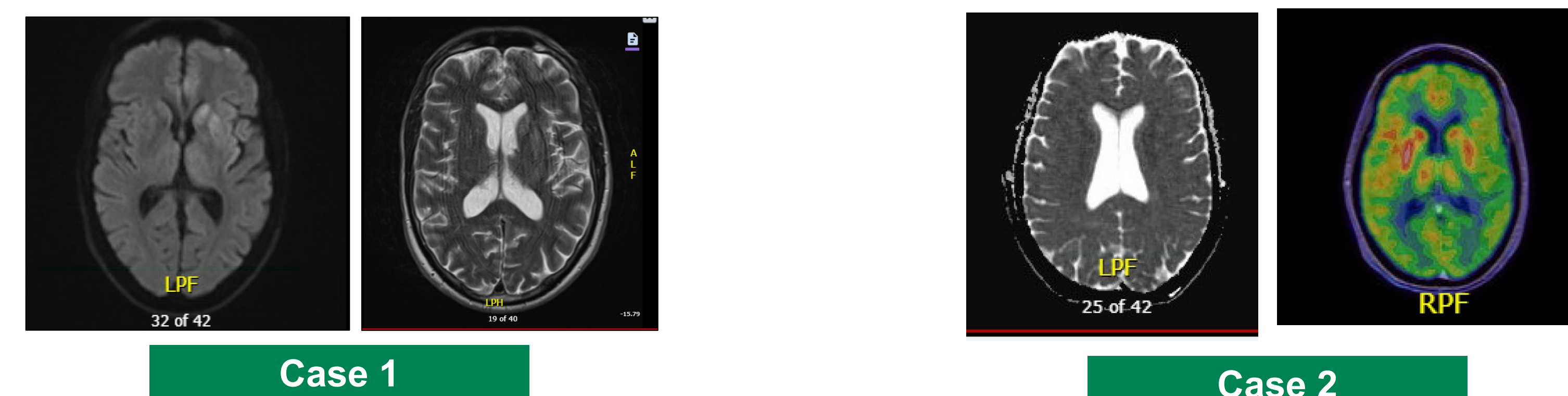
	CASE 1	CASE 2
HISTORY	<p>66-year-old previously High functioning Caucasian male with:</p> <ul style="list-style-type: none"> <li>• PPH of Bipolar I disorder (on Clonazepam only);</li> <li>• One prior inpatient hospitalization (for mania);</li> <li>• No prior suicide attempt admitted to the Geriatric inpatient unit for acute mania and psychosis following a car accident.</li> </ul> <p>Collateral information: decline in general functioning for last 6 months including cognitive function.</p> <p>FH: schizophrenia and suicide (biological brother).</p>	<p>63-year-old previously High functioning female with:</p> <ul style="list-style-type: none"> <li>• PMH of OSA;</li> <li>• LRRK-2 gene (Parkinson disease risk);</li> <li>• No prior psychiatric history who presented for a second opinion for progressive gait instability, movement disorder and altered mental status.</li> </ul> <p>Prior admission neurological work-up was negative including brain imaging, lumbar puncture, and EEG. Diagnoses of FND was made.</p>
EXAM	<p>Mania with grandiosity, elevated and expansive mood, and disinhibition.</p> <p>Psychosis with grandiose delusions and Ideas of reference.</p> <p>Unilateral R hand resting tremor and shuffling gait + pronator drift on the R + proximal RLE. <b>No clonus or myoclonus.</b></p>	<p>Gait difficulty, right greater-than left-sided postural/action&gt;rest tremor, <b>myoclonus like jerks</b>, dysarthria/stuttering, and right-sided sensory deficit + functional neurologic features (distractibility, stuttering, exaggerated efforts, poor stereotyping).</p> <p><b>BFCRS:</b> total score = 42 including mutism, posturing, echopraxia, moderate rigidity, gegenhalten, ambitendency) and waxy flexibility.</p>
DATA	<p><b>EEG:</b> negative for seizure activity</p> <p><b>MoCA:</b> 20/30 (twice)</p> <p><b>MRI Brain w/o contrast:</b> Restricted diffusion/high T2/FLAIR signal involving portions of the left basal ganglia and left anteromedial temporal lobe + mild generalized volume loss.</p> <p><b>MRI Brain w/ contrast</b> Non-enhancing restricted diffusion involving medial cortices of the left inferior frontal lobe and left basal ganglia, left amygdala and to lesser extent the left insular cortex with corresponding abnormal signal.</p>	<p><b>EEG:</b> triphasic waves + positive for seizure activity on lateral parietal occipital region, periodic pattern with sharp contours in L centroparietal region.</p> <p><b>MRI Brain wo/w:</b> Increased DWI gyriiform signal hyperintensity on both L and R parietal areas.</p> <p><b>Brain PET:</b> Diffuse cortical hypometabolism, slightly more pronounced in the bilateral central and bilateral occipital region with left-sided asymmetry. There is relatively increased FDG uptake in the right putamen, left amygdala.</p>
DX	<p>Bipolar I disorder, most recent manic episode, with psychotic features</p> <p>↓</p> <p>CJD (via RT-QuIC with: positive RT-Quic, elevated Tau protein and 14-3-3)</p>	<p>Functional Neurologic Disorder with Catatonia</p> <p>↓</p> <p>CJD (via RT-QuIC result: elevated Tau protein and 14-3-3)</p>

## Cases Series Presentation

T X	Developed parkinsonism with PO Haldol and confusion with Lithium, but tolerated and responded effectively to Valproic Acid PO ER 250 mg at bedtime.	Catatonic symptoms unresponsive to Lorazepam (excessive sedation), zolpidem (excessive sedation), and memantine (not effective), amantadine (not effective).  Fair response to Valproic Acid 500 mg IV.
O U T C O M E	Hospice care, continued Depakote PO. Passed away 31 days after discharge.	Patient died during the medical inpatient hospitalization.

PPH – past psychiatric history, PMH: Past medical history; PO = per os, ER = extended release ; OSA (sleep apnea); BFCRS = Bush-Francis Catatonia Rating Scale; RUE = Right upper extremity; FND = functional neurologic disorder; MOCA: Montreal Cognitive Assessment; FDG: 18F-fluorodeoxyglucose.

## Graphics



**Graphics 1-2:** Examples of MRI Brain (without and with contrast) with associated imaging abnormality for cases 1.

**Graphics 3-4:** Examples of cortical ribboning on brain MRI and brain PET FDG abnormalities in case 2.

## Discussion

- While CJD is historically characterized by neurological symptoms, acute mania and severe catatonia can be an early feature.
- Red flags include **1) minimal psychiatric history, 2) rapidly progressing symptoms, 3) concomitant neurologic symptoms** and a **4) poor response** to standard psychiatric treatments.
- Currently, there are limited guidelines for identifying or treating psychiatric disorders with medical etiologies.
- However, CJD should always be considered as a secondary cause of mania or catatonia and if suspected, warrants targeted imaging and laboratory workup.
- Furthermore, it highlights the importance of a multidisciplinary approach and heightened clinical suspicion to ensure a timely diagnosis.

## References

1. Cadick, A. L., Ehresman, R. M., & Jones, J. A. (2022). Identifying medical mimics for late-life mania: A case of prion disease. *The International Journal of Psychiatry in Medicine*, 57(3), 202-211.  
<https://doi.org/10.1177/00912174211010529>
2. Mead S, Rudge P. CJD mimics and chameleons *Practical Neurology* 2017;17:113-121. doi:10.1136/practneurol-2016-001571.
3. Foster, H., Barker, A., Nirodi, P. and Ahmed, Y. (2022), Diagnostic overshadowing in sporadic Creutzfeldt-Jakob disease?. *Prog. Neurol. Psychiatry*, 26: 12-15. <https://doi.org/10.1002/pnp.743>